

A Teaching Module on musculoskeletal injuries in migrant farmworkers for the migrant health clinician



Module I: Shoulder Injuries

Module created by Katrina L. Harris, D.O.

Diagnosis and Treatment-Shoulder Injuries



MODULE I: SHOULDER INJURIES

Objectives:

- Review musculoskeletal injuries in agricultural workers
- Risks for shoulder injuries in migrant farmworkers
- Diagnosis and treatment of shoulder injuries
 - ~ anatomy and physiology of the shoulder
 - ~ taking an occupational history
 - ~ specific shoulder disorders: history/mechanism of action, physical exam, diagnostic tests, treatment, prevention

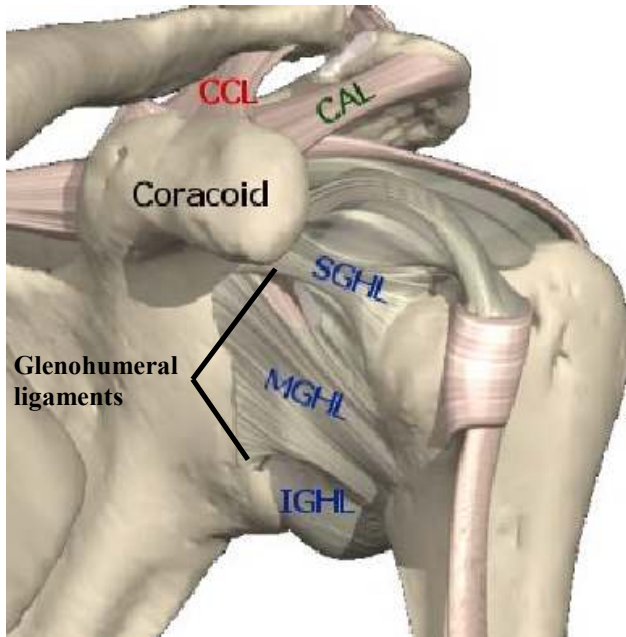
Risk Factors for Musculoskeletal Disorders of the Shoulder:

- Working with arms elevated (more than 60° of flexion or abduction)
- Static postures
- Static loading
- Heavy lifting and forceful exertion
- Repetitive arm movements
- Insufficient rest

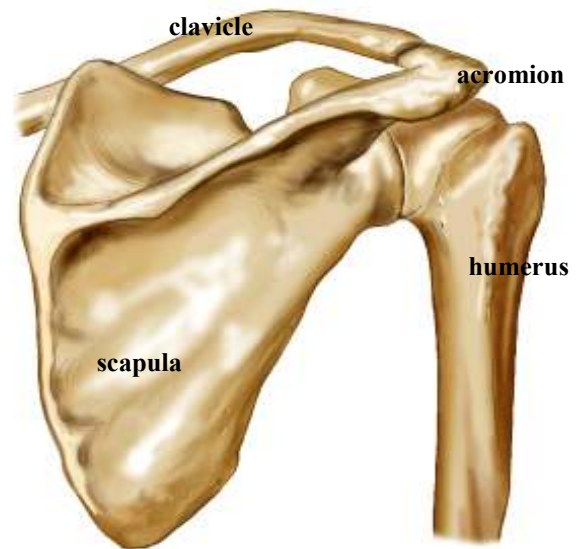
- A NIOSH epidemiological review states that “the evidence for the greatest risk of musculoskeletal disorders due to specific shoulder postures is strongest when there is a combination of exposures to several physical factors such as force and repetitive load /i.e./ holding a tool while working overhead.”



Bones and Ligaments



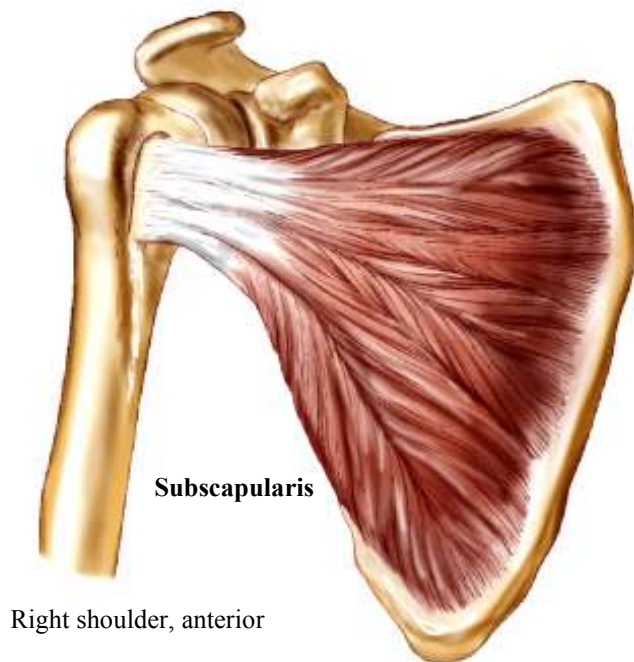
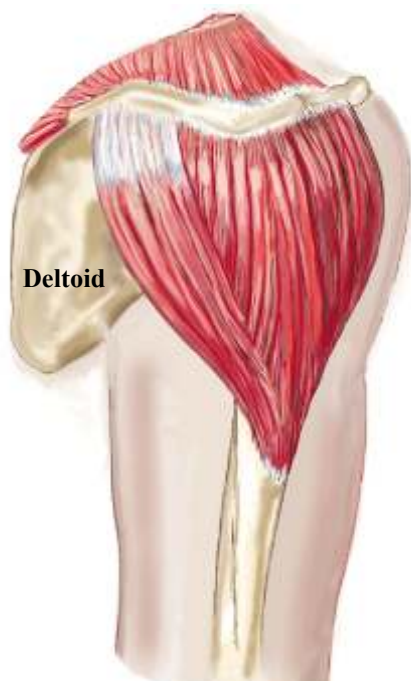Left shoulder, anterior



Right shoulder, posterior

www.shoulderdoc.co.uk. 2003.

Muscles and Tendons



Right shoulder, anterior

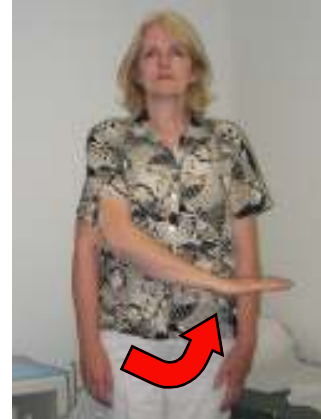All images on this page, unless otherwise stated, from the MediClip Color Human Anatomy II Collection, 1996, Williams & Wilkins, A Waverly Company

Movement of the shoulder: Muscles used



Abduction:

-deltoids
-supraspinatus



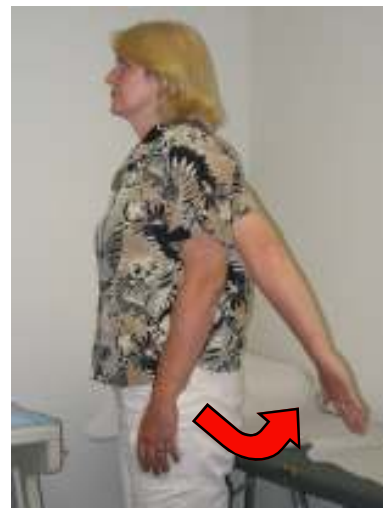Adduction:

-pectoralis major -teres major
-latissimus dorsi -subscapularis



Flexion:

-deltoids



Extension:

-latissimus dorsi

Internal rotation:

pectoralis major
latissimus dorsi
teres major
subscapularis



External rotation:

deltoids
infraspinatus

Physical Exam: Inspection, palpation, range of motion, strength testing, special maneuvers, ruling out red flags

Special Maneuvers

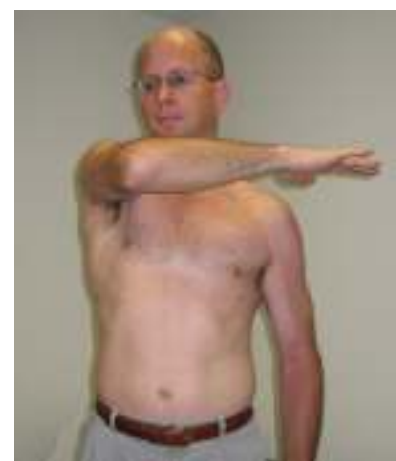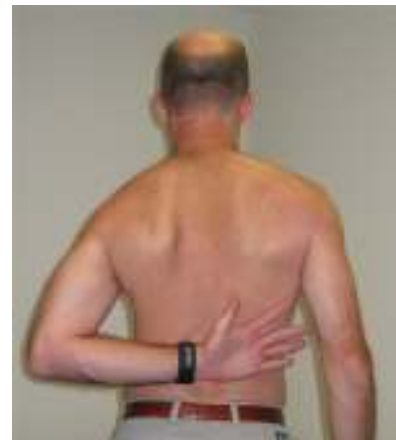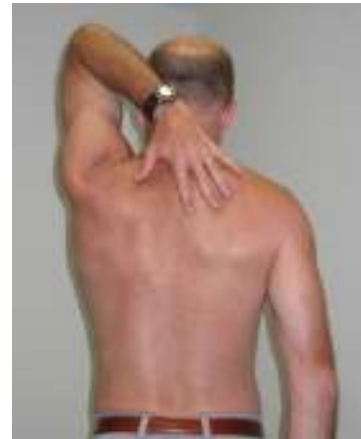Apley scratch test:

- First the patient touches the superior aspect of the contralateral scapula with their fingertips by reaching their arm behind their head.
- This will test abduction and external rotation.
- Next the patient touches the inferior aspect (or as close as they can get) with the dorsal aspect of their fingers reaching their arm up behind their back.
- This tests adduction and internal rotation.

Asymmetry or problems with the maneuver may indicate an injury to the rotator cuff.

Cross-arm test:

- Patient actively flexes the arm at the shoulder to 90° then adducts it across the front of the chest.
- This test is used to isolate acromioclavicular joint sprain and distinguish it from impingement syndrome.



Special Maneuvers

Drop-arm test:

- With arms fully abducted the patient is asked to slowly adduct their arms.
- If one side drops quickly (starting at 90), this indicates a rotator cuff tear. The patient will be able to hold his arm in abduction however even a light tap will cause his arm to drop uncontrollably.



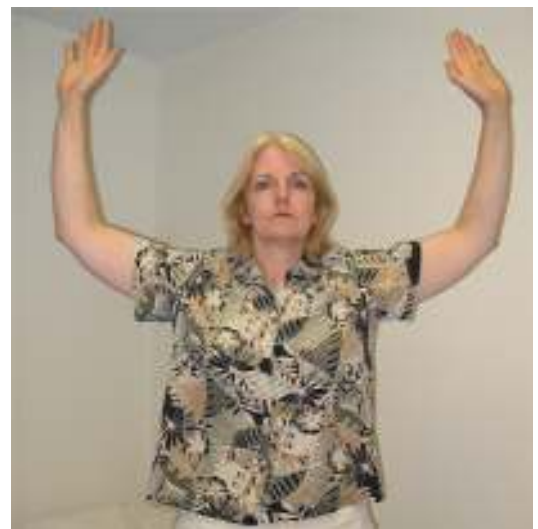“Empty can” test:

- The patient is asked to abduct arms against resistance with elbows extended and the arms internally rotated (thumbs pointing down like pouring soda out of a can).
- Inability to perform this test because of pain or weakness indicates a problem in the supraspinatus muscle.



“NFL” touchdown sign:

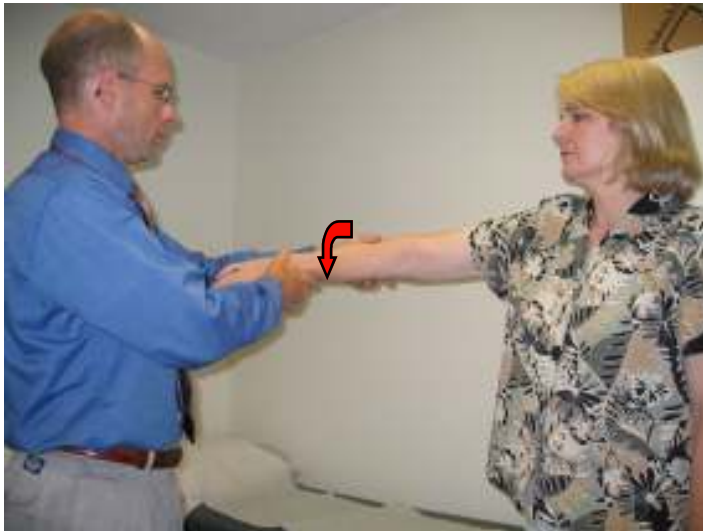- Patients abduct their arms over their head.
- This motion can evaluate range of motion and look for asymmetries in terms of smoothness of motion, amount of discomfort and achieving full abduction.
- The first 25° of abduction involve only the glenohumeral joint.
- Above 25° the scapulothoracic articulation comes into play.
- Beyond 120° the arm must be able to externally rotate to complete abduction.



Special Maneuvers

Neer's sign:

- Patient is asked to internally rotate their arm and with the scapula stabilized with one hand the examiner passively places the arm in full flexion at the shoulder joint.
- Pain with this action indicates impingement of the supraspinatus tendon.




Hawkins' test:

- Similar to Neer's sign, except that patient's arm is flexed to 90° with the elbow also flexed at 90°.
- Then the arm is passively internal rotated.
- Pain with this is thought to indicate subacromial impingement of the supraspinatus tendon or tendinitis.



RED FLAGS



Rule out:

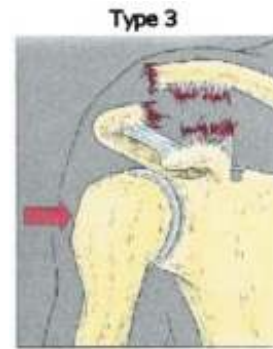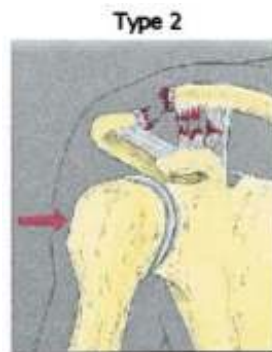
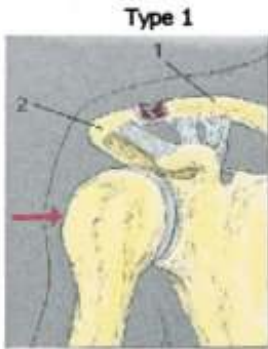- septic arthritis
- gout or pseudo-gout
- heart disease
- lung disease
- gastrointestinal diseases
- cervical arthritis or
- degenerative disk disease

Shoulder pain may be referred pain from any organ innervated by C3-T1 or irritation of the diaphragm

Common diagnoses

fractures
dislocations
sprains/ separations
rotator cuff tears
impingement
syndromes
tendinitis

AC joint sprain (“shoulder separation”)

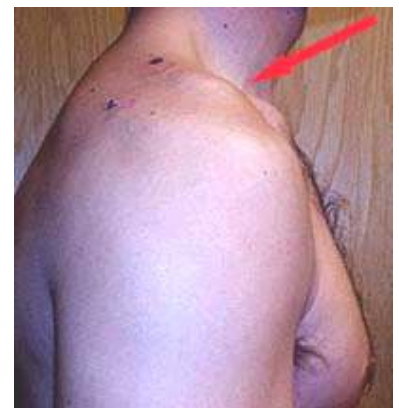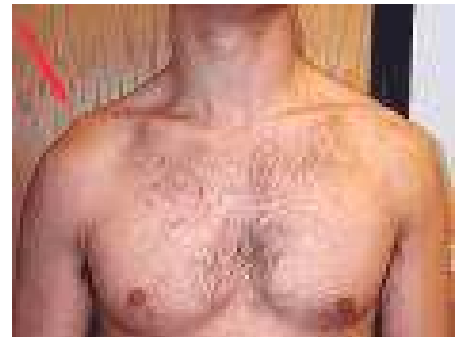


Images from www.shoulderdoc.co.uk

- 6 grades (I-VI)
- The higher the number the more severe the displacement and the more likely the patient will need surgery.

History/Mechanism of action:

- Forceful blow either to the superior or lateral aspect of the shoulder
- Occasionally with a fall on an outstretched arm
- Pain over AC joint
- Limited range of motion
- Edema, ecchymosis
- Shoulder deformity



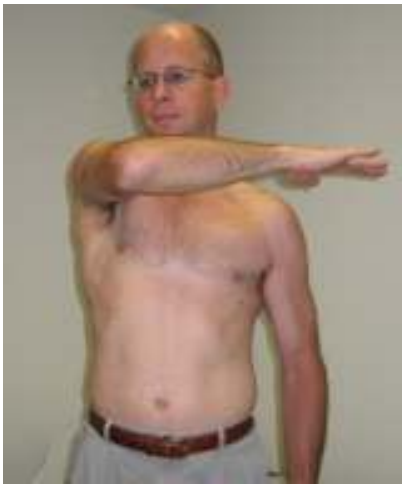Physical exam:

- Edema and tenderness to palpation over the AC joint
- Severe dislocations may have a palpable step off deformity between the acromion and the clavicle

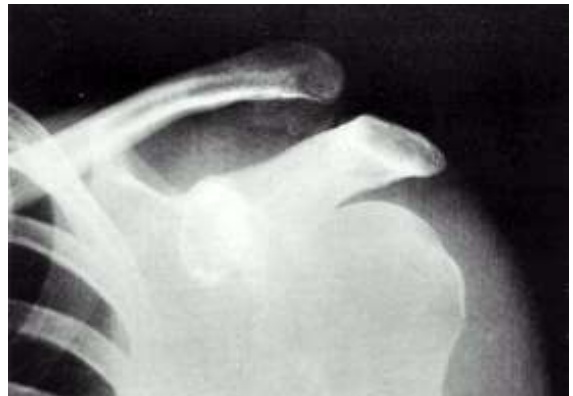AC joint sprain (“shoulder separation”)

Diagnostic tests:

Cross arm test can be used to distinguish from impingement.



An AP x-ray usually confirms the diagnosis and an auxiliary view is helpful in further defining more severe separations.



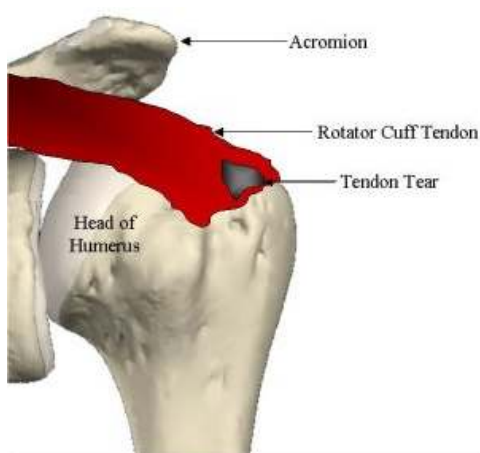Treatment:

- Grade I-III lesions are usually treated conservatively
- Ice 20 - 30 minutes every 3 - 4 hours for 2 - 3 days
- Sling immobilization
- Range of motion exercises to start 1-2 weeks after injury
- At least 2 -4 weeks before returning to full activity
- Grade IV-VI separations require surgical repair
- After surgery usually at least 2 months is needed before resuming full activity
- Grade III may also require surgery if an individual has an occupation that requires heavy lifting

Prevention:

- Shoulder strengthening exercises
- Securing ladders and other objects that might fall and hit superior shoulder

Rotator cuff tear



www.shoulderdoc.co.uk

- Most often seen in patients over 40 years of age.
- Often associated with impingement syndrome.
- Tears are most often seen in infraspinatus and supraspinatus tendons.
- Partial tears may be seen in patients age 30-50 and are usually limited to the supraspinatus tendon.
- Full thickness tears are often disabling even with treatment.

History/Mechanism of action:

- Unexpected or overwhelming load placed on the arm (catching a heavy falling object)
- Landing on an outstretched arm
- Pushing or pulling of heavy weight or resistance (pulling a cable to start a lawn mower)
- Repeated overhead movements
- Trouble actively elevating arm
- Trouble externally rotating arm
- Shoulder pain worsening pain at night
- Lifting heavy objects

Physical exam:

- Atrophy of the rotator cuff muscles
- Crepitus of the subacromial region
- Tenderness over the greater tuberosity of the humerus
- Limitation with elevation of the arm and external rotation
- Restricted motion or positive test with Apply Scratch, Drop Arm and Empty Can tests

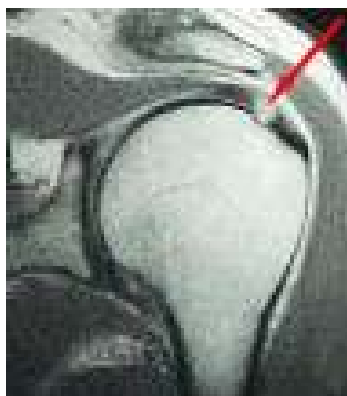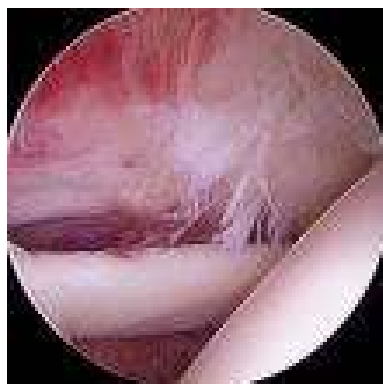


Diagnosis and Treatment-Shoulder Injuries

Rotator cuff tear

Diagnostic tests:

- The gold standard is the double-contrast arthrogram.
- MRI is most commonly used and has a 95% sensitivity and specificity in identifying full thickness tears.
- Ultrasound may also be used to diagnose full thickness tears, but gives less overall information about the soft tissue structures than MRI.



Treatment:

Conservative treatment:

- Ice for 20 - 30 minutes every 3 - 4 hours for 2 - 3 days
- NSAIDs
- Range of motion exercises
- Cortisone injections
- Sling may be used during period of acute pain

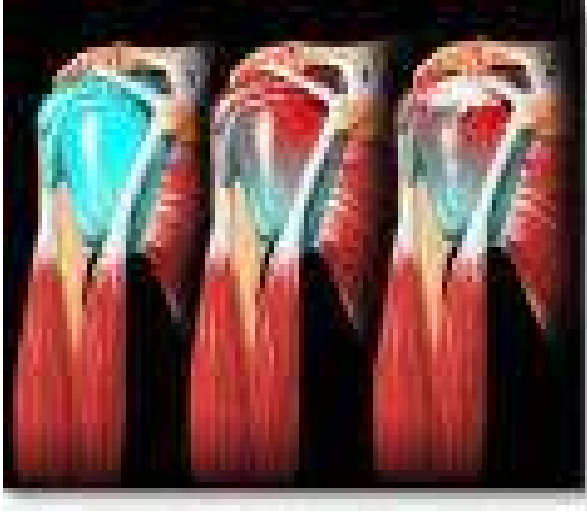Surgical treatment:

- Acute large full thickness tears
- Young active workers
- Those who do not improve after 3 months of conservative therapy
- ROM exercises should be initiated immediately after surgery
- Medium activity may be resumed after six months of therapy
- Heavy work should not be resumed for a full year after surgery

Prevention:

- Rotator cuff strengthening exercises
- Strengthening of scapula stabilizer muscles
- Proper posture and lifting techniques
- Limitation of overhead work
- Adequate rest breaks during over head work

Impingement syndrome



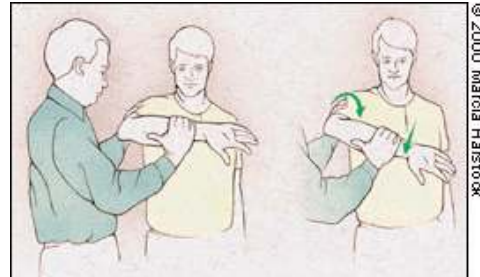
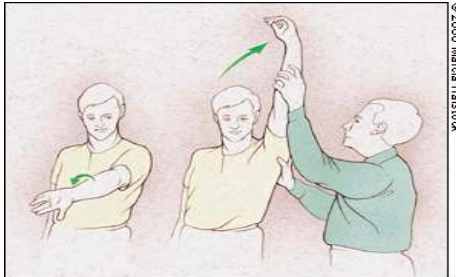
- Neer originally described this syndrome in three stages:
 1. Swelling and bleeding (usually seen in patients less than 25 years in age).
 2. Tendinitis and fibrosis (usually seen between the ages of 25 and 40).
 3. Tendon degeneration and possible rupture with bony spur formation at the acromion (most often in patients older than 40).

History/Mechanism of action:

- Overuse injuries associated with extended periods of working with hands over head and motions involving shoulder circumduction (hoeing soil).
- *Primary impingement syndrome* is usually seen in older patients who have developed arthritic changes of bone and ligaments secondary to past trauma or overuse.
- *Secondary impingement syndrome* is often seen in younger patients with fatigue of the rotator cuff muscles, subacromial bursitis and resultant glenohumeral instability with superior migration of the humerus.
- Pain over the anterolateral aspect of the shoulder often radiating down to the elbow.
- Pain worse when doing activities which require the arms to be raised above the shoulders.
- Pain worse if patient lays on the affected shoulder.

Impingement syndrome

Physical exam and diagnostic tests: Positive Neer's sign and Hawkin's test



- Impingement syndrome may be confirmed if the above tests are negative after injection of 10cc of local anesthetic in the subacromial space.
- AP x-ray with the arm externally rotated at 30°, Y view and axillary view may all be helpful in showing AC and glenohumeral arthritis and calcific tendinitis.
- X-rays will only diagnose primary impingement syndrome.

Treatment:

- Conservative therapy with NSAIDs and range of motion exercises is the most common treatment.
- Forward elevation with the arm internally rotated should not be done until the patient has been pain free for at least three months as this replicates the impingement.
- Subacromial cortisone injections may also be helpful, but are limited secondary to the risk of tendon rupture with repeated uses.
- The majority of patients will get better without surgical intervention.
- Surgical subacromial decompression is a last resort in those patients who show no improvement and are limited in their activities of daily living.
- Young patients with secondary impingement may need to undergo a surgical procedure to stabilize their rotator cuff.

Prevention:

- Rotator cuff strengthening exercises
- Limitation of overhead work